Stony Brook Cancer Center

Collaborative Medical Vision for Precision Medicine: The Quest for Interpretable and Explainable ML Models

Prateek Prasanna, PhD
Assistant Professor, Department of Biomedical Informatics

Imagine Lab

Stony Brook University
College of Engineering and Applied Sciences

AI-Informed Clinician

Clinician-Informed AI

Imperfect Data Scenarios where Clinician-AI collaboration is important

- ❑ Missing Modalities [MICCAI '23, ICCV '23]
- ❑ Costly Annotations [ICLR '23, ECCV '22, NeruIPS '23]
- ❑ Scarcity of datasets [MICCAI '23, IPMI '23]
- ❑ Unpaired data [CVPR '22]
- ❑ Complex Reasoning [CVPR '24, MeDIA'24]

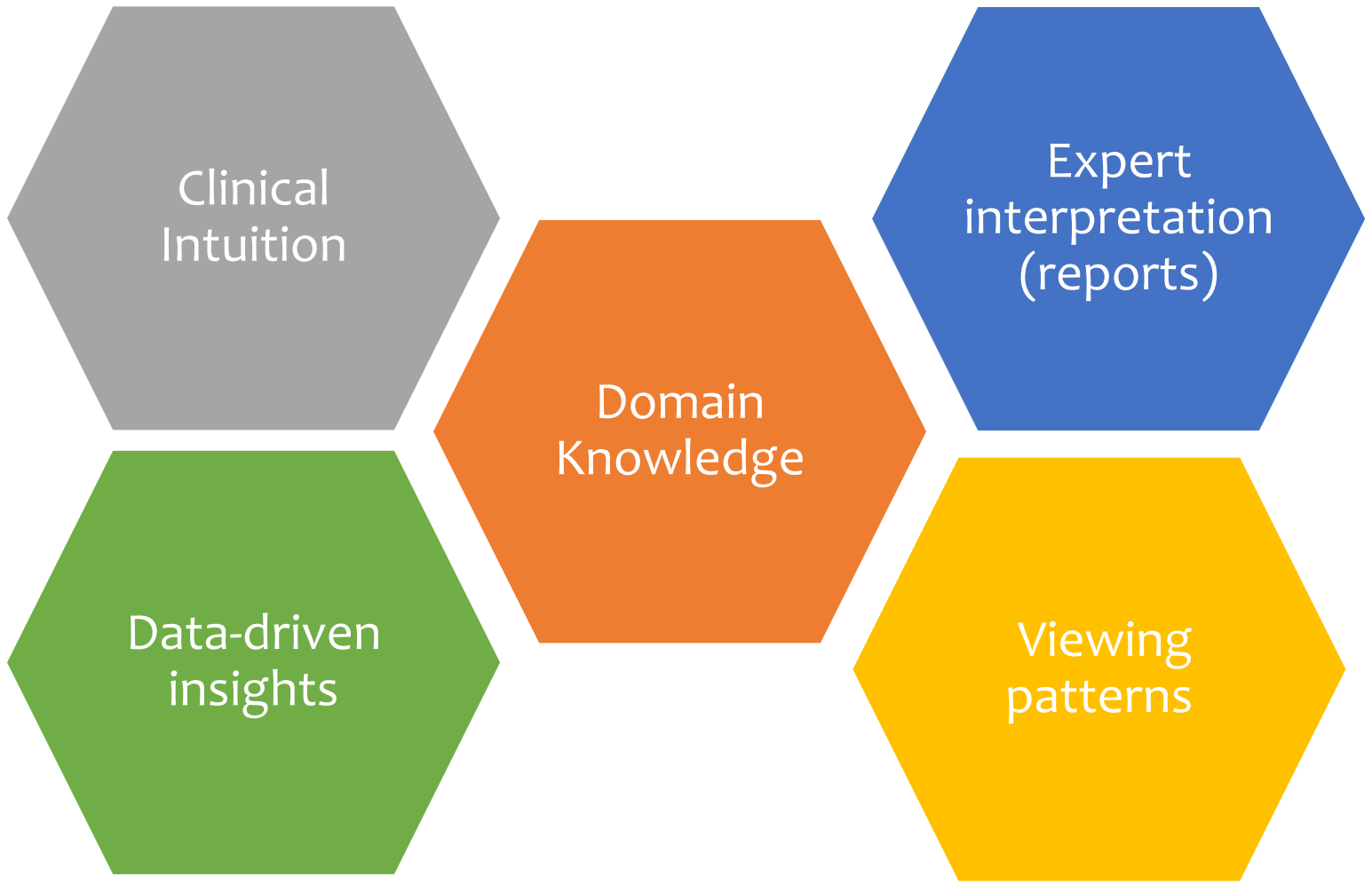

From purely data-driven models to…

Data-informed and domain-inspired models

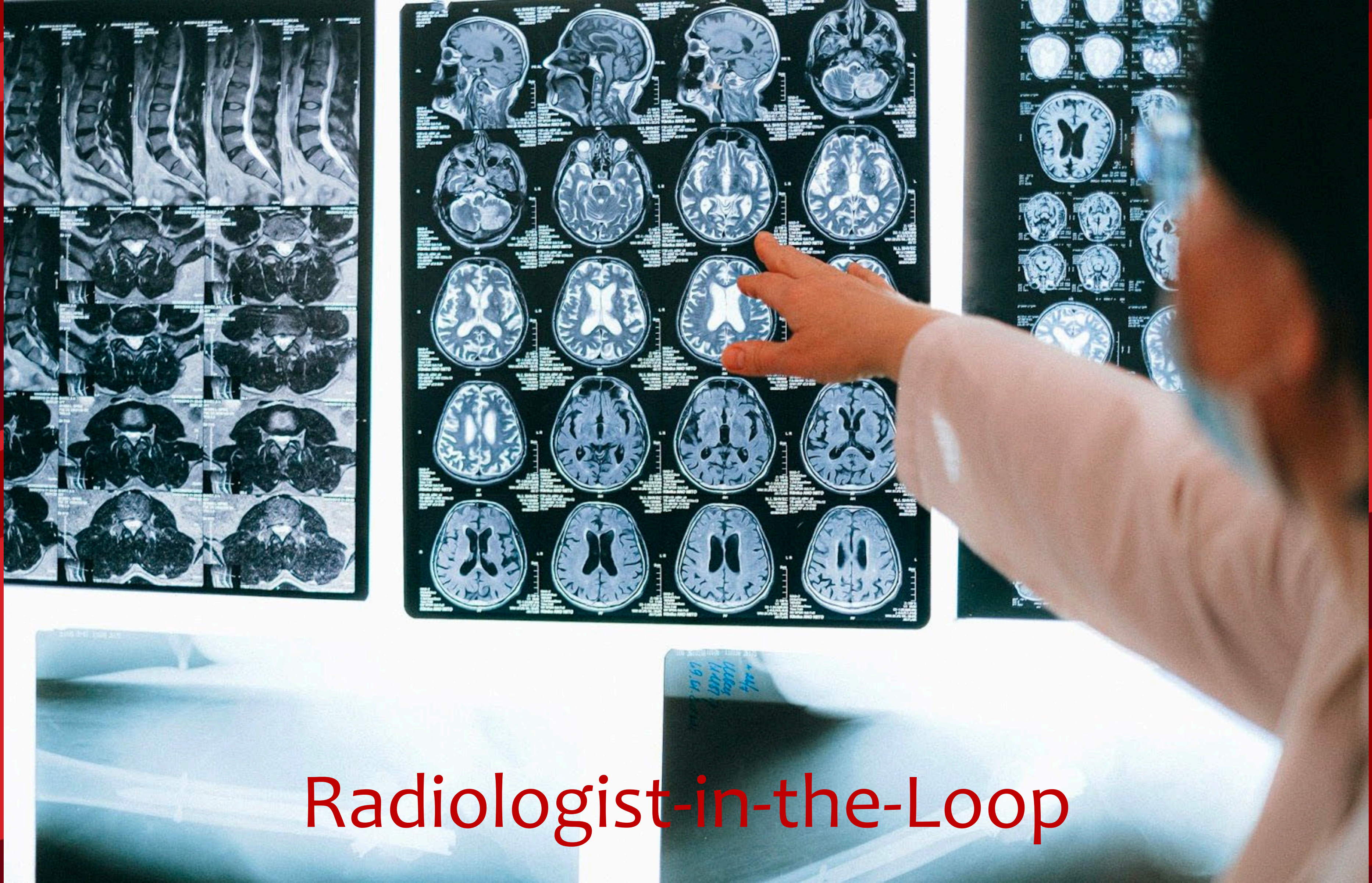

Radiologist-in-the-Loop

Can Radiologists' Eye Gaze Information Augment ML decisions?

Deep Learning based Analysis

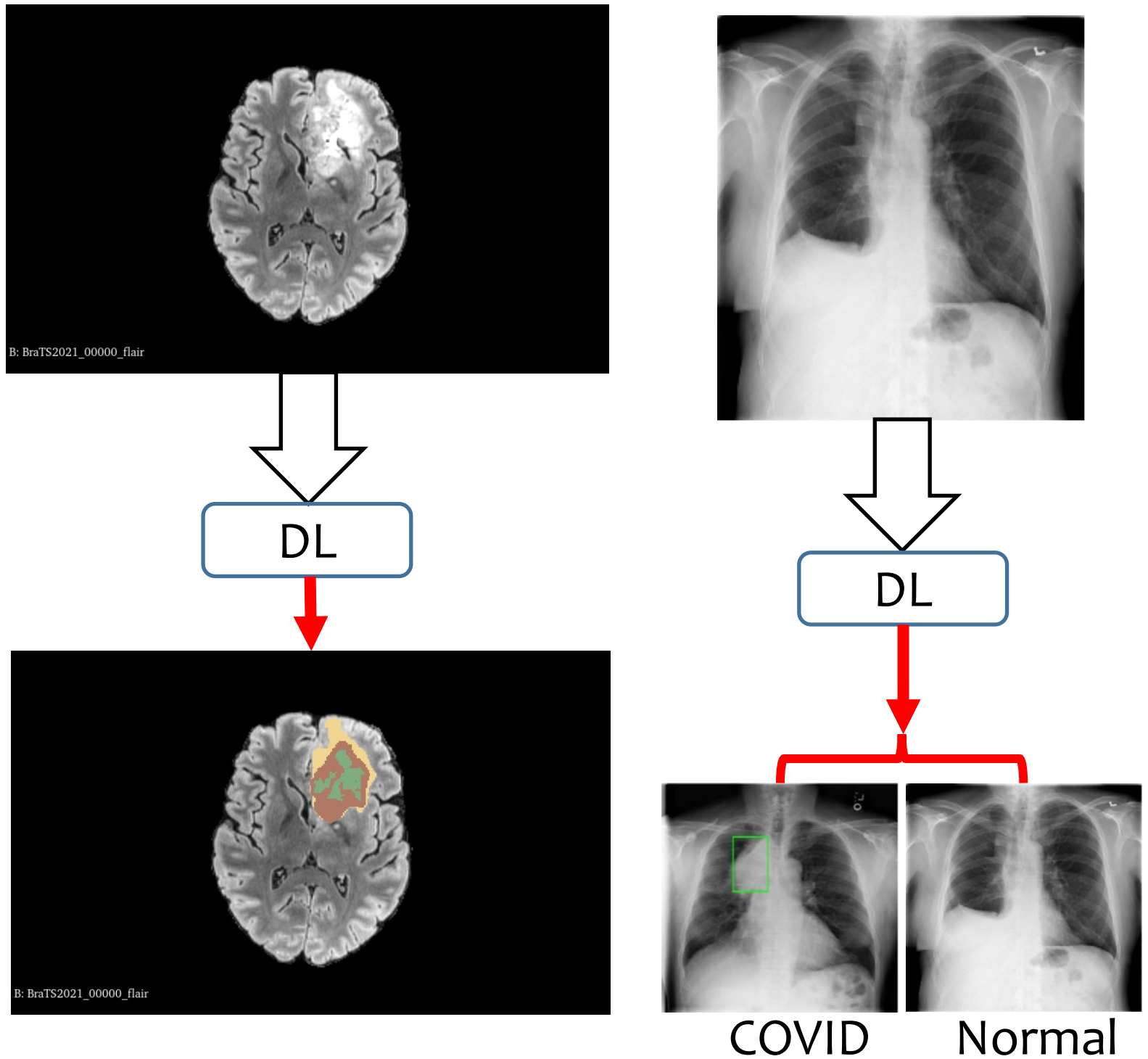

Radiomic Analysis

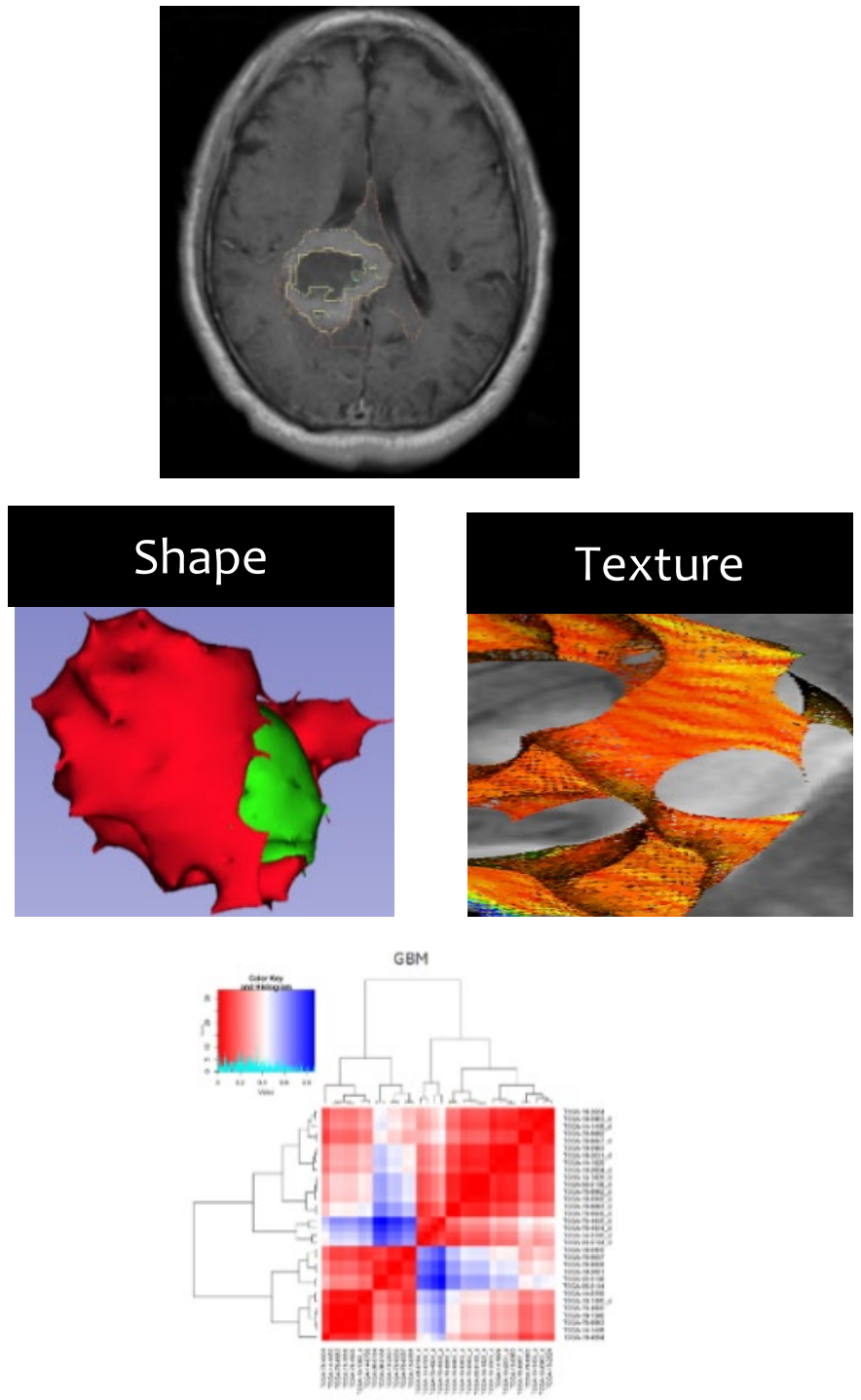

Tumor grading

Radiologist Eye-gaze maps

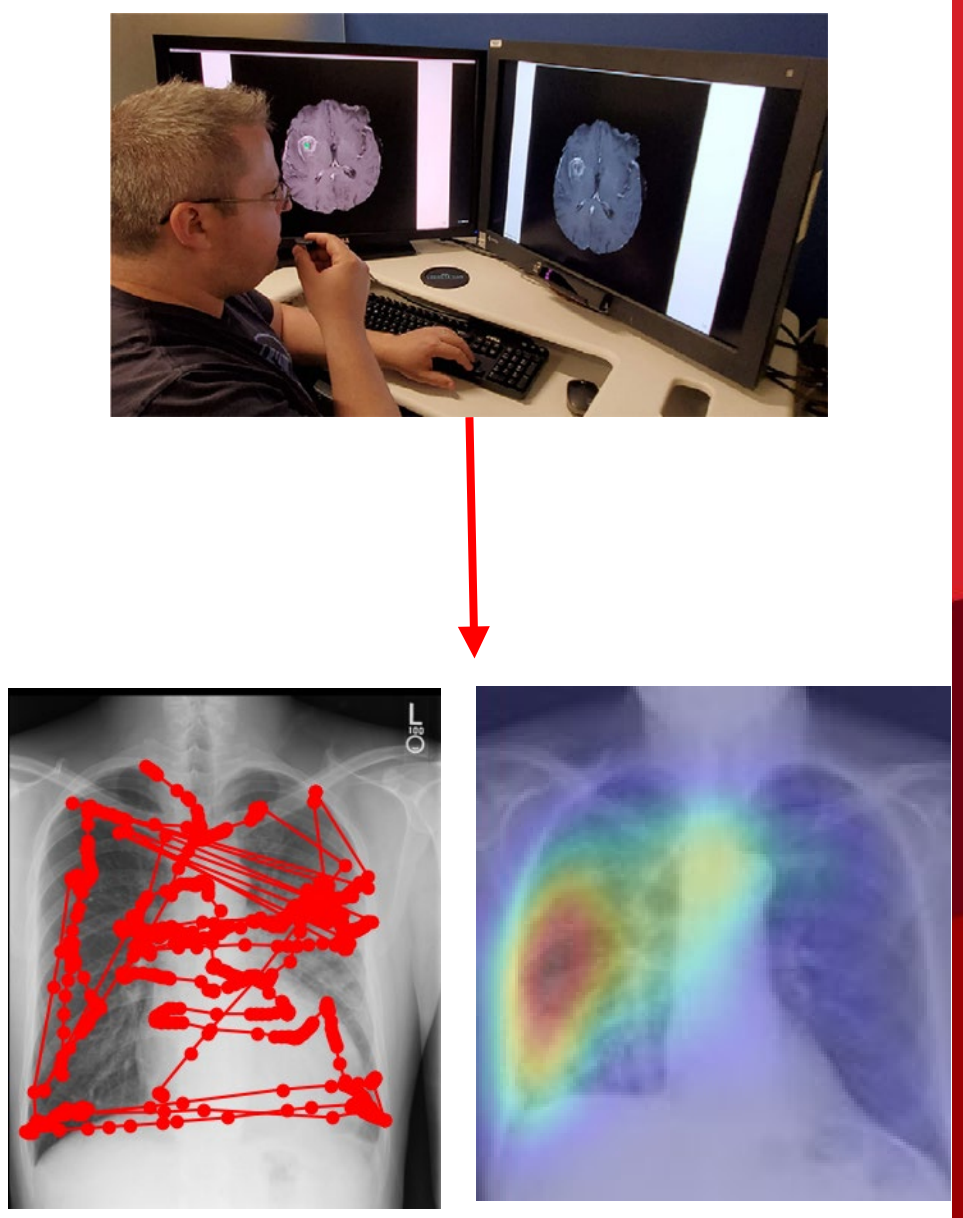

RadioTransformer: A Cascaded Global-Focal Transformer for Visual Attention–guided Disease Classification

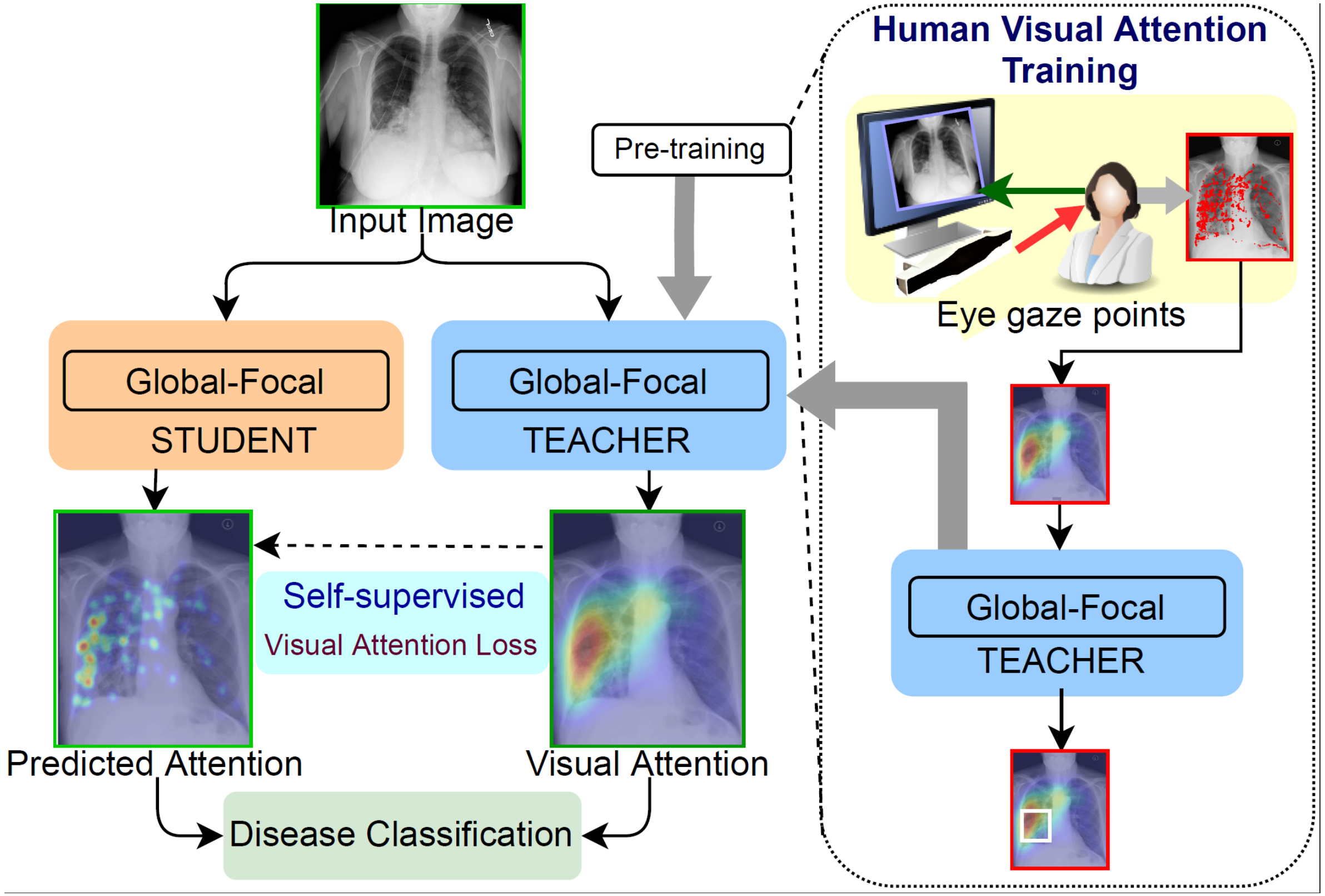

Bhattacharya et al, MICCAI 2022, ECCV 2022

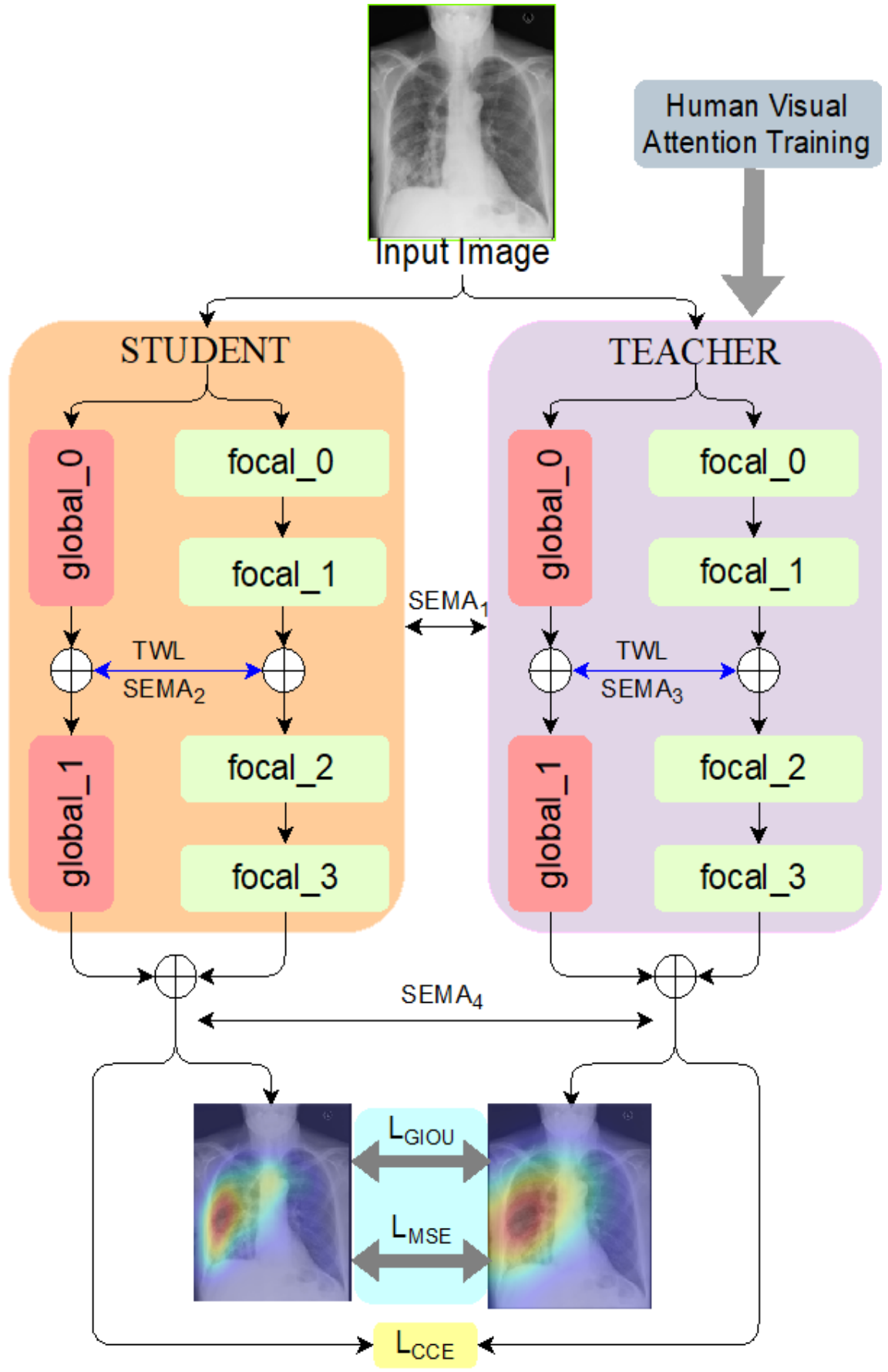

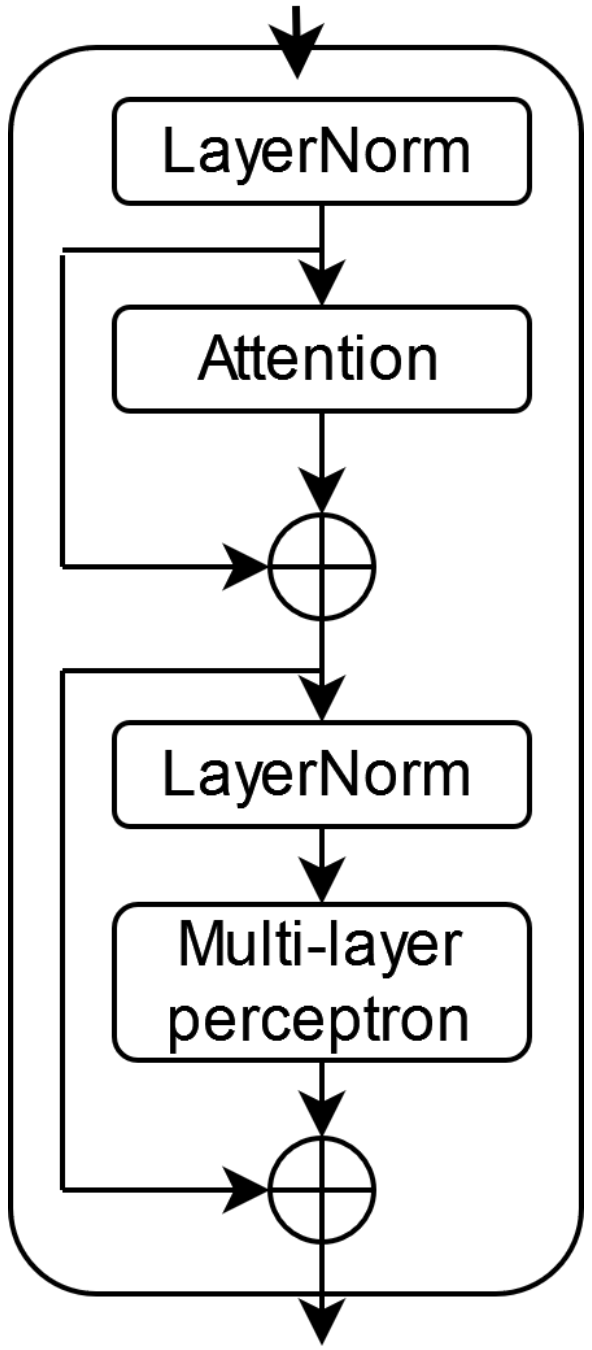

- A <u>global-focal transformer architecture</u> to capture coarse-fine search behavior of radiologists.
- Global module learns high-level coarse representations and the focal module learns low-level granular representations.

Classification→	Pneumonia				COVID-19				14-Thoracic				COVID-19 (Test)			
Dataset→	Cell [33]		RSNA [69]		SIIM [37]		Rad [9, 62]		NIH [86]		VBD [56]		MIDRC [76, 77]		SBU [11, 67]	
Architectures↓	F1	AUC	F1	AUC	F1	AUC	F1	AUC	F1	AUC	F1	AUC	F1	AUC	F1	AUC
R50 [18]	59.78	81.70	93.75	98.91	43.01	98.85	94.03	99.27	11.91	74.04	21.76	95.86	23.04	96.32	15.11	65.16
R101 [18]	71.93	83.64	94.84	99.21	39.22	96.98	85.36	97.62	11.20	73.30	32.77	96.24	22.31	93.87	24.22	99.20
R152 [18]	74.30	*87.49*	91.97	98.57	43.04	98.18	70.21	87.90	10.67	71.37	32.42	96.58	19.22	83.09	**24.58**	**99.61**
R50v2 [19]	*78.96*	87.32	96.60	99.44	47.99	99.79	92.82	99.06	11.42	73.11	34.11	96.32	23.93	98.72	18.71	78.27
R101v2 [19]	52.11	71.23	96.39	99.33	45.83	99.26	97.46	99.82	11.99	73.46	32.18	96.55	04.86	42.13	19.43	82.47
R152v2 [19]	53.44	71.97	95.30	99.01	47.10	99.71	97.76	99.82	11.93	73.23	32.69	96.54	23.07	95.89	23.03	96.25
D121 [20]	70.05	81.97	96.25	99.34	47.59	99.82	95.72	99.51	13.81	78.83	28.71	96.01	24.88	99.82	20.67	88.35
D169 [20]	59.18	76.56	88.86	95.60	46.40	99.68	94.33	99.52	**15.21**	79.90	32.90	96.46	24.97	99.84	20.13	85.95
D201 [20]	71.93	82.98	95.43	99.04	*48.17*	**99.83**	*97.81*	99.85	14.84	81.38	34.66	96.41	**24.99**	**99.99**	21.08	89.53
ViT-B16 [12]	73.85	83.40	76.35	86.06	36.22	95.74	88.25	98.42	05.50	82.06	34.80	95.69	08.47	42.15	11.49	50.22
ViT-B32 [12]	70.02	76.41	79.11	90.74	30.42	92.12	86.73	98.09	06.51	83.77	30.57	94.58	17.50	76.52	18.26	77.75
ViT-L16 [12]	69.59	83.31	85.41	94.53	34.16	95.75	90.11	98.70	08.16	81.60	33.99	95.40	11.17	47.79	15.54	62.72
ViT-L32 [12]	76.38	87.07	69.32	88.86	28.45	92.54	88.40	98.35	06.35	84.96	33.24	95.36	10.21	47.35	03.92	30.82
CCT [17]	62.10	71.18	80.60	92.04	32.63	95.33	92.52	99.11	08.08	85.37	30.25	95.12	23.98	98.53	19.43	83.21
Swin0 [44]	66.04	83.74	96.27	99.57	47.63	99.66	97.53	*99.92*	07.90	74.62	34.30	95.08	13.74	63.07	17.77	75.47
Swin1 [44]	73.74	86.91	*96.65*	*99.58*	47.30	99.56	94.94	99.64	08.30	74.18	34.27	95.13	15.47	69.00	17.64	73.68
RadT w/o (HVAT+VAL)	**79.56**	**89.82**	97.85	99.78	48.42	99.69	98.13	99.94	05.97	**85.48**	**37.64**	96.83	16.70	71.78	22.19	93.75
RadT	77.40	88.80	**98.75**	**99.85**	**48.74**	99.65	**99.39**	**99.98**	04.21	85.43	37.32	**96.84**	18.17	79.60	22.18	94.76

Immunotherapy Response Prediction

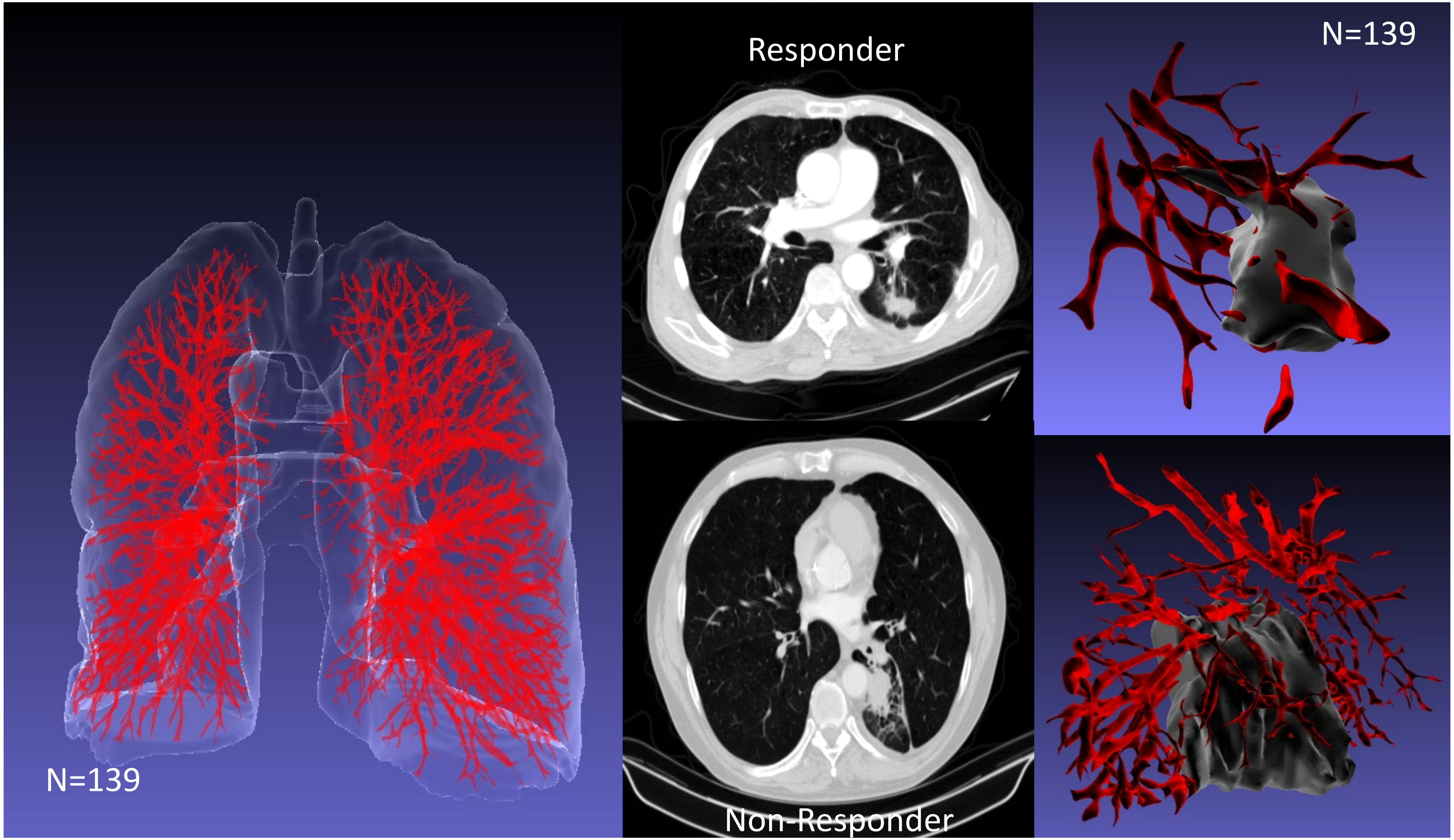

Science Advances 2023

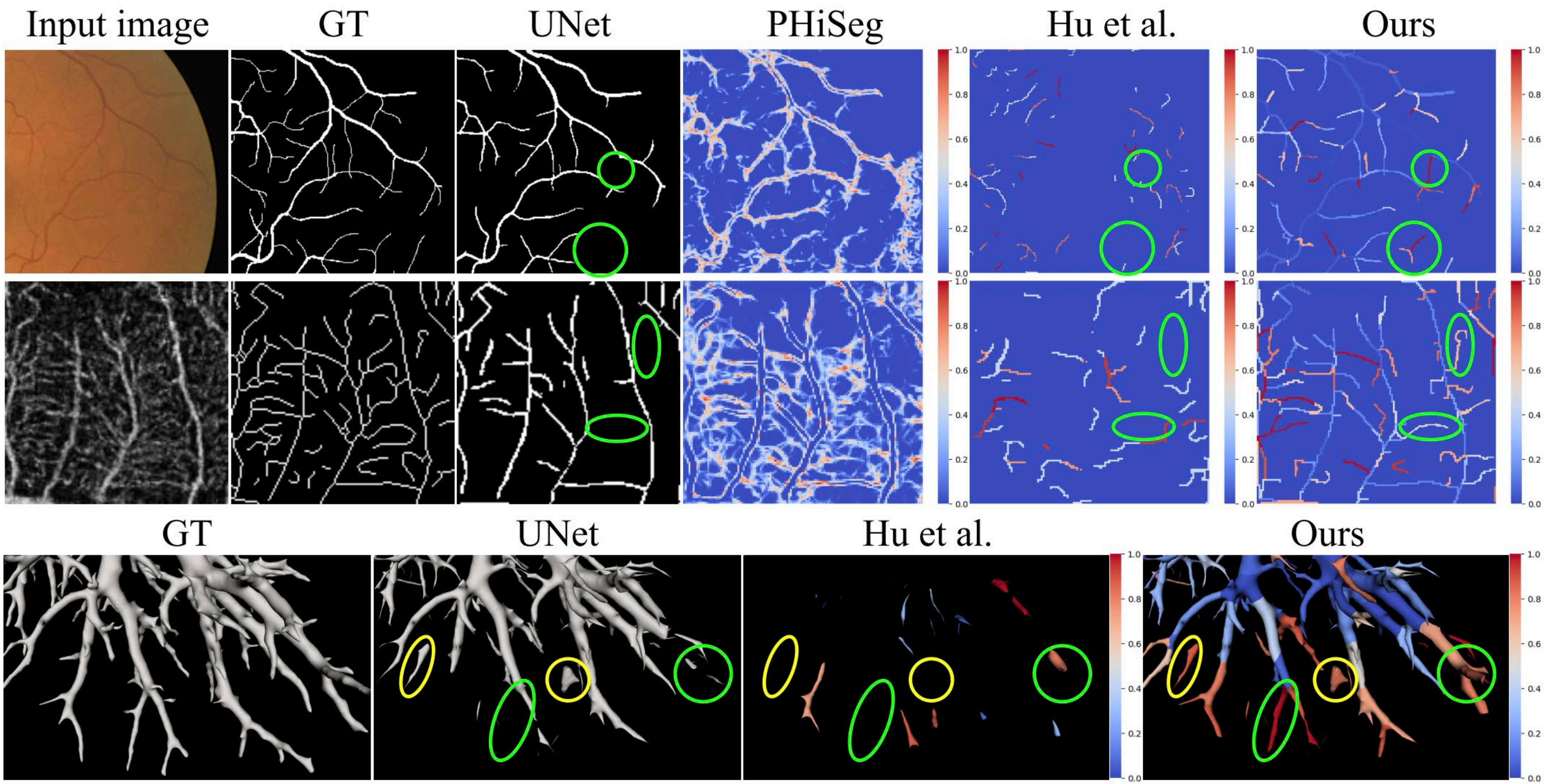

How do we use uncertainty estimation to efficiently obtain high fidelity segmentations?

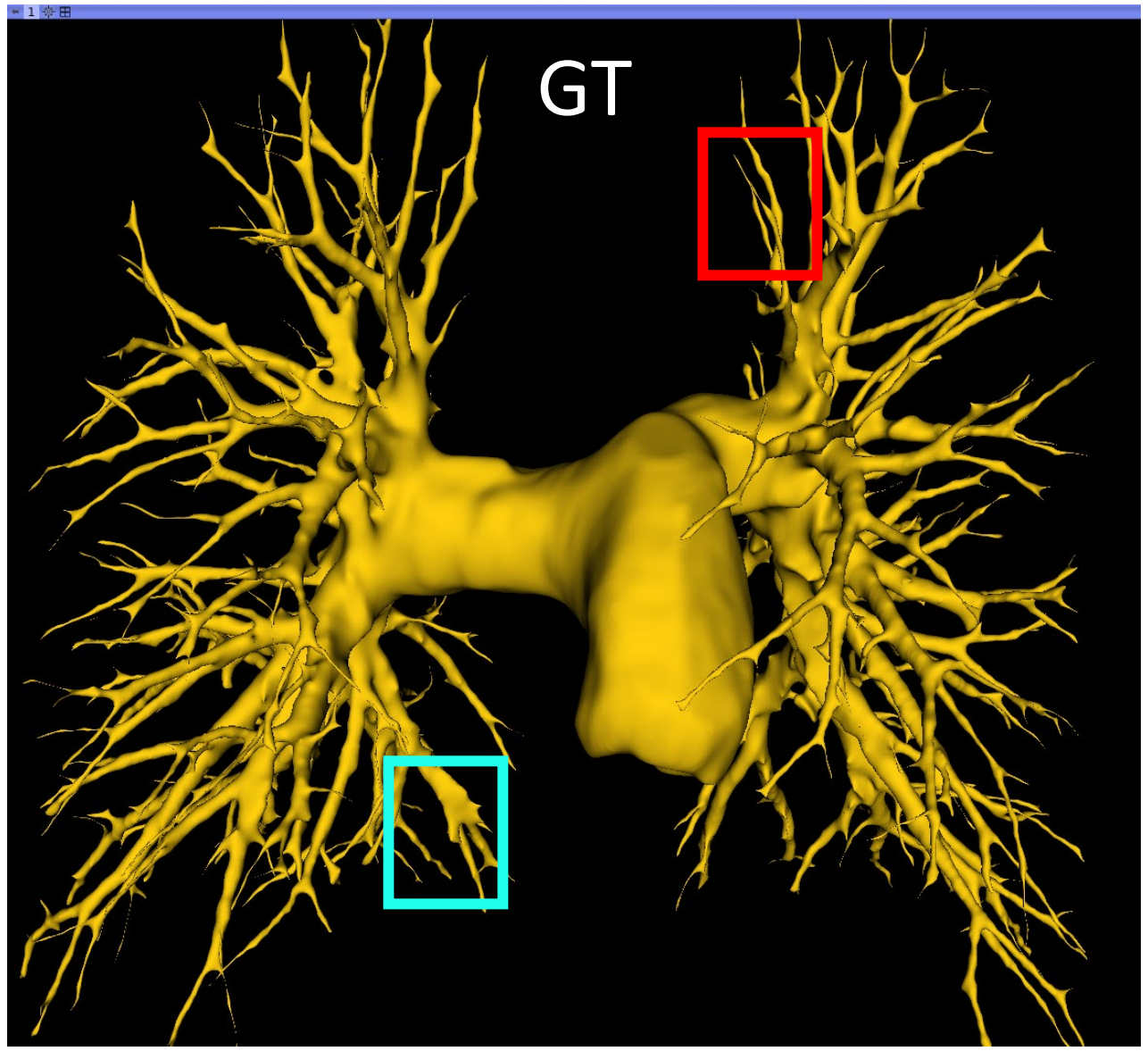

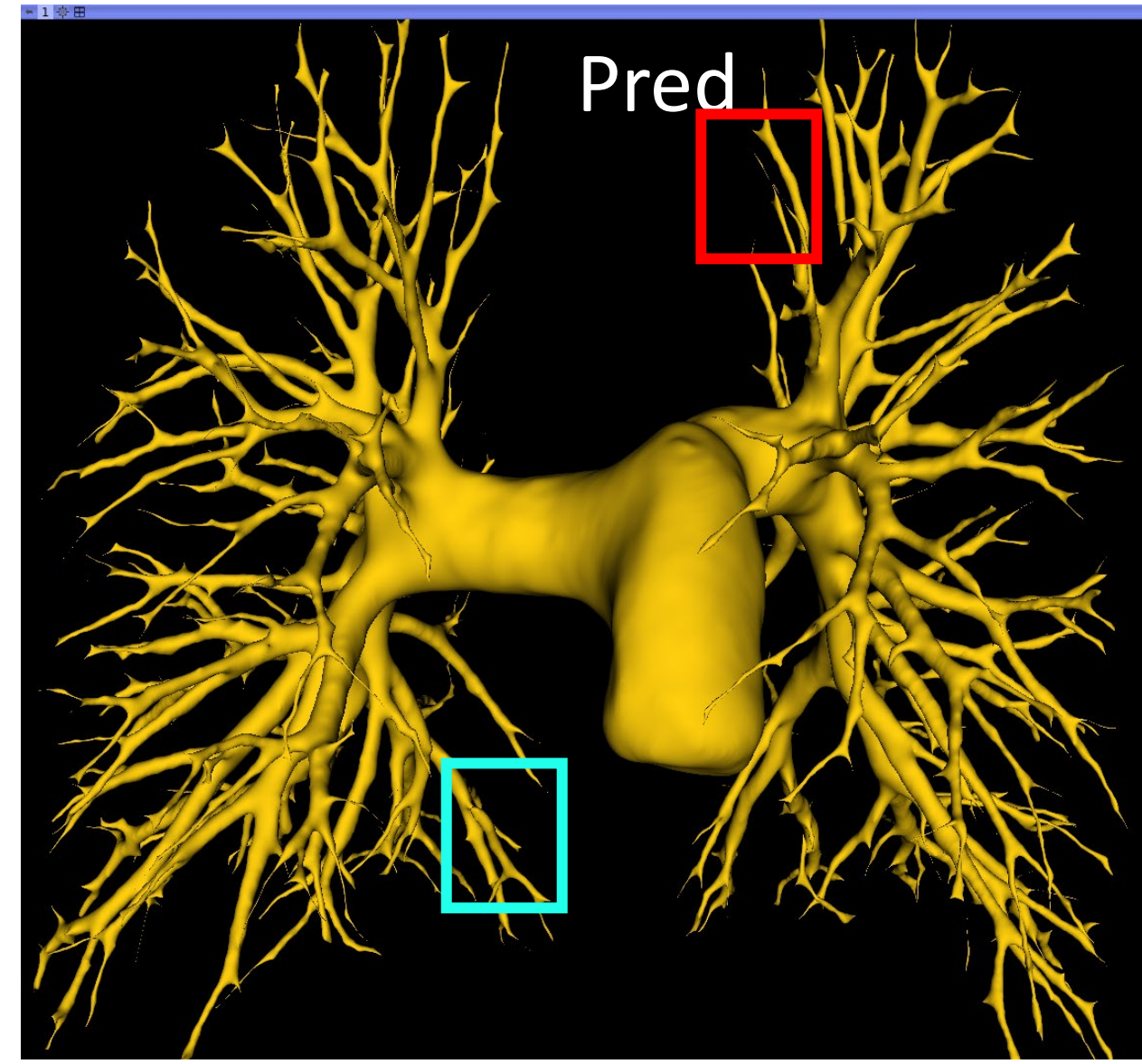

Gupta et al,
NeurIPS 2023

Uncertainty estimation-driven interactive segmentation

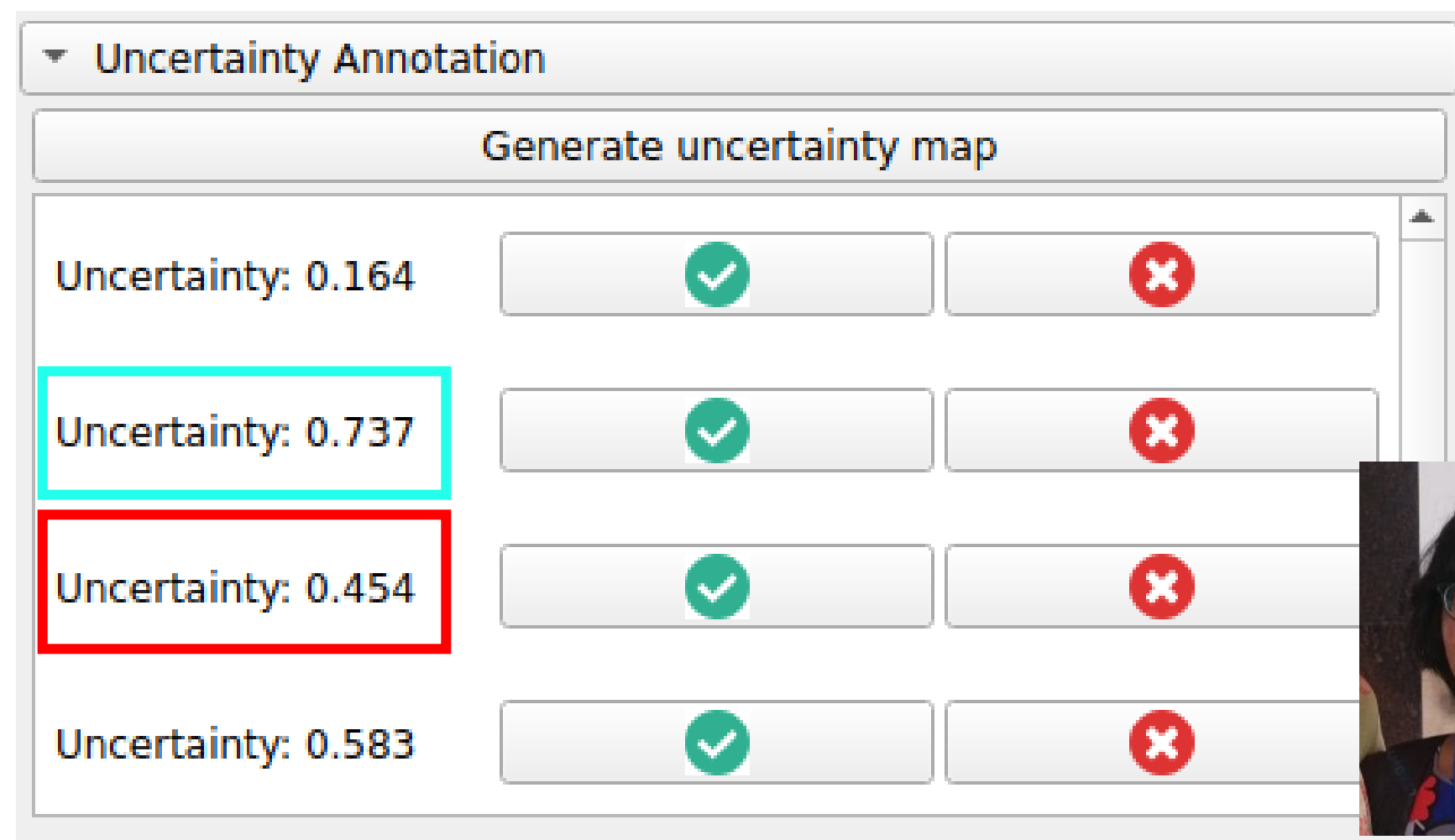



Pathologist-in-the-Loop

Interpretability in Computational Pathology: From Black-box to Glass-box

- Identifying salient regions in a WSI

- Several MIL methods provides the visualization of attention maps from the learned patch-level attention.

- Though useful, they may not offer an automated understanding of the model's prediction due to a lack of user-friendly feature grounding.

- Also these visualizations are hard and subjective for experts to interpret.

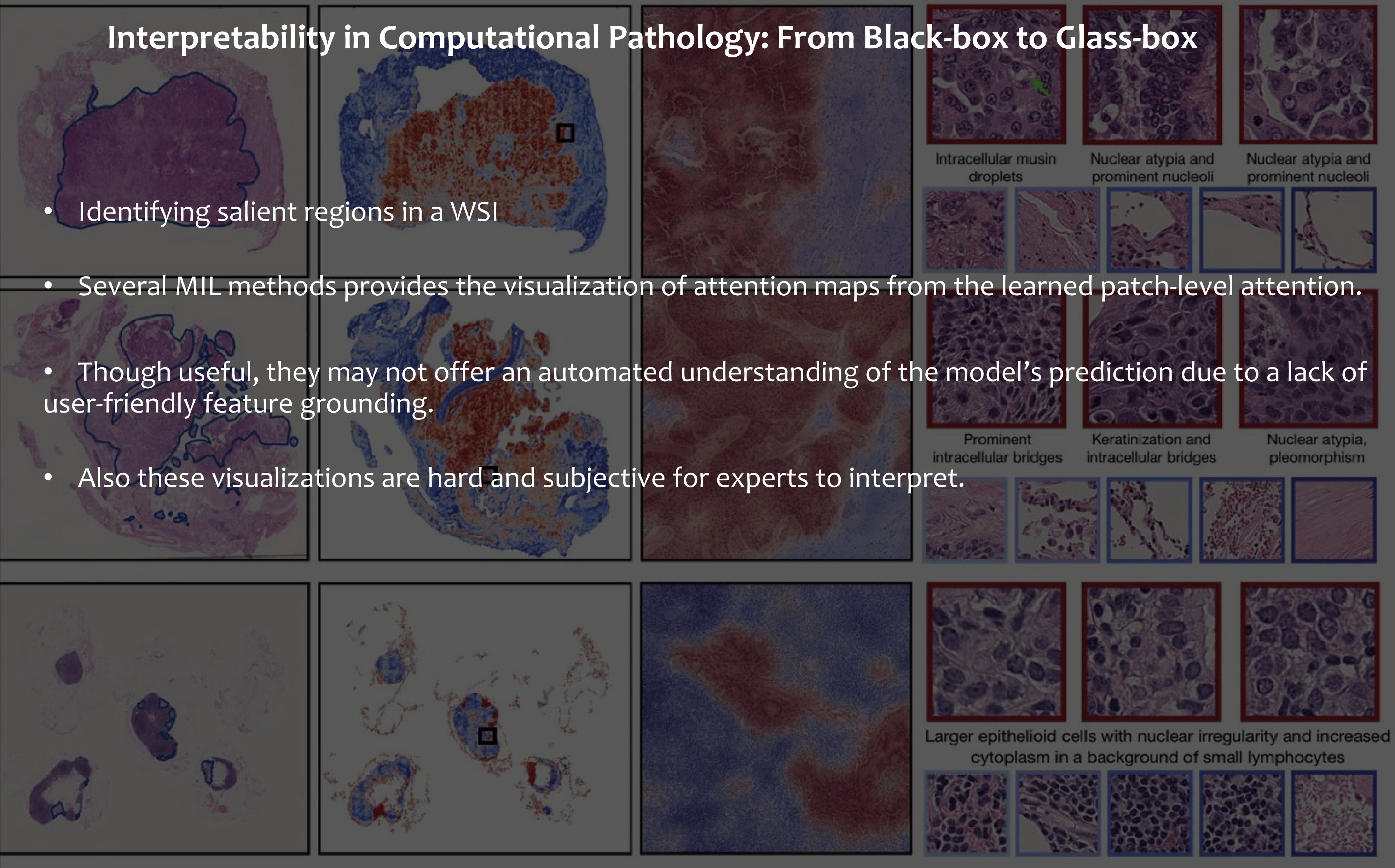

Whole slide image classification

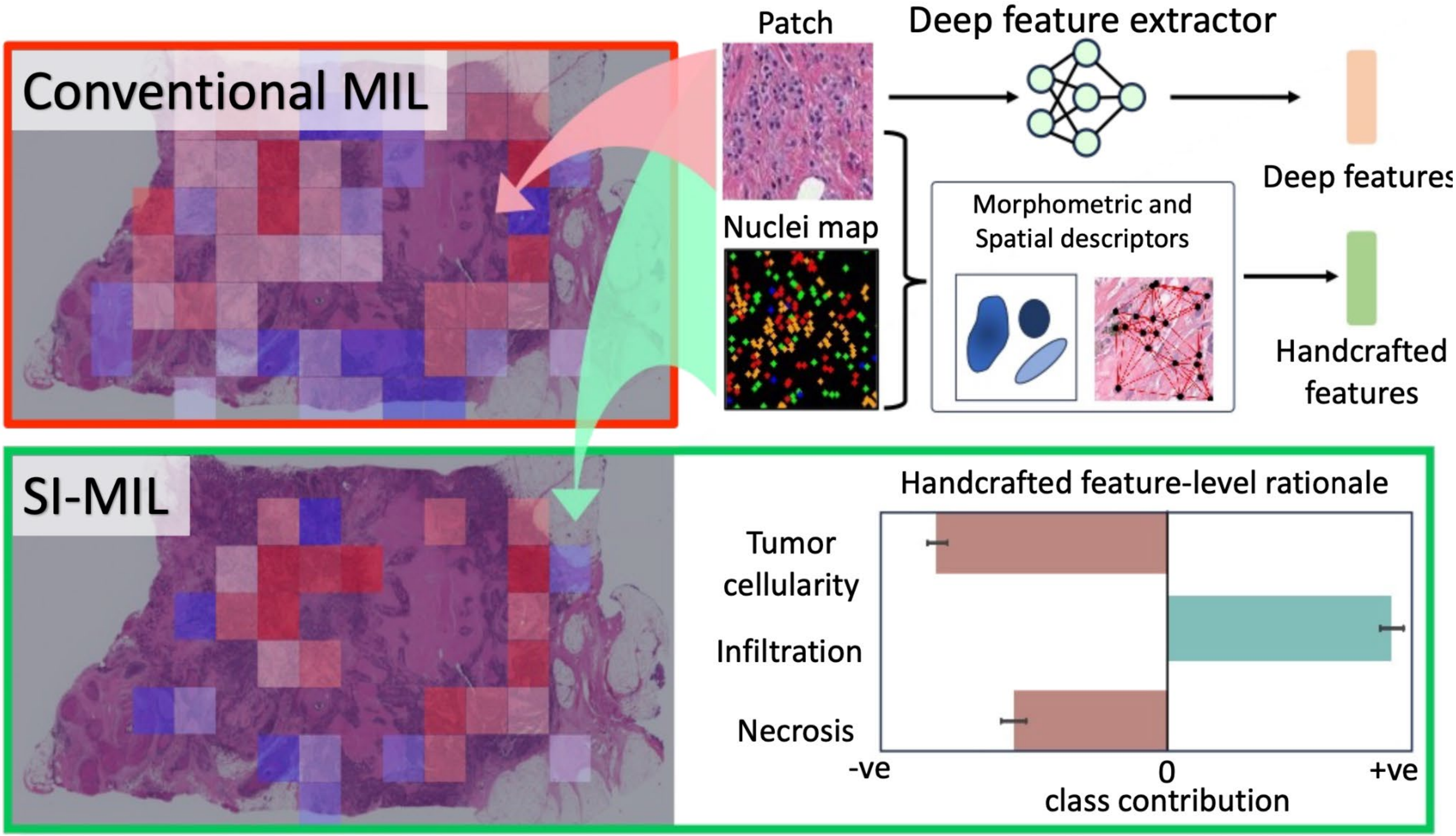

Proposed method – Self Interpretable Models

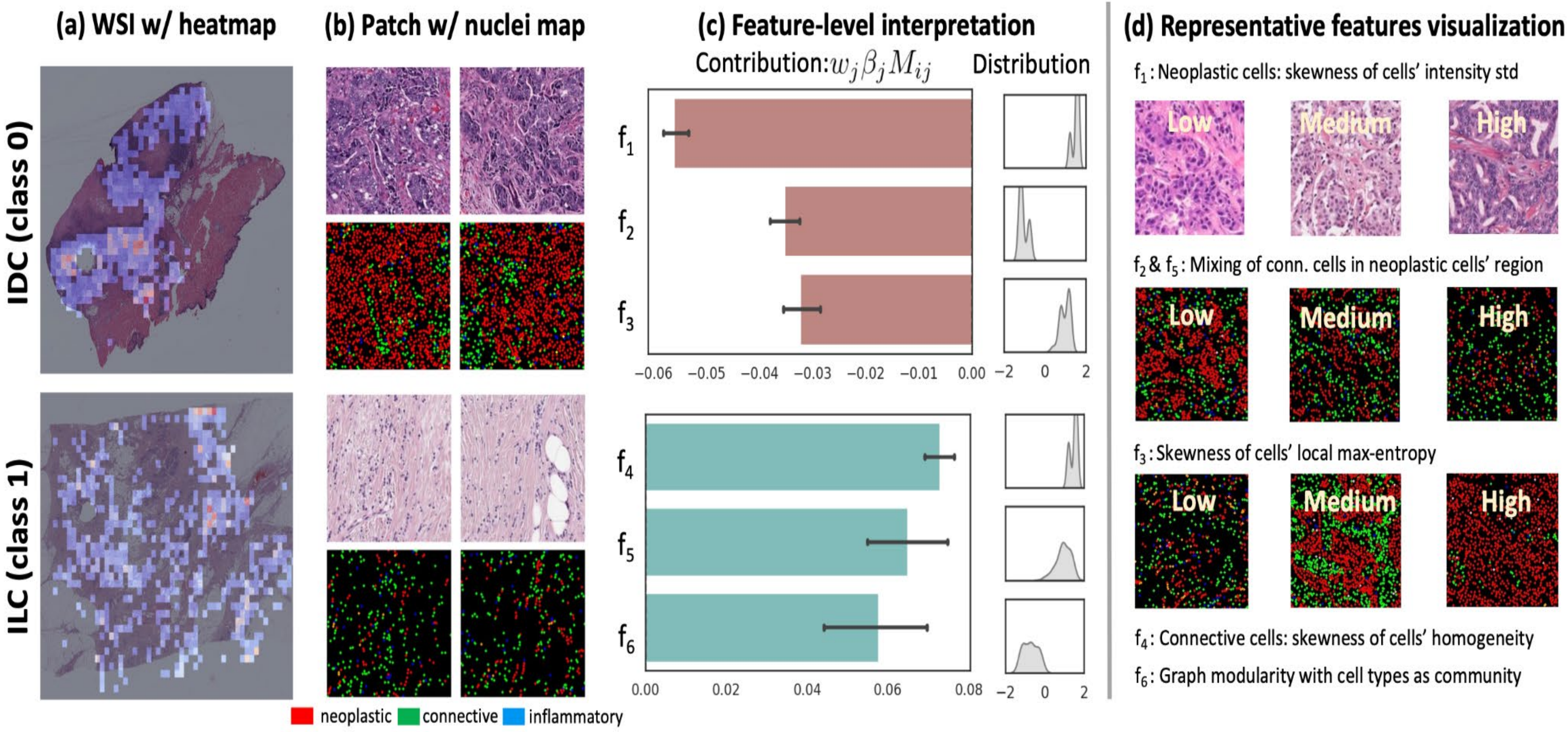

Kapse et al, CVPR 2024

Text-conditioned image generation

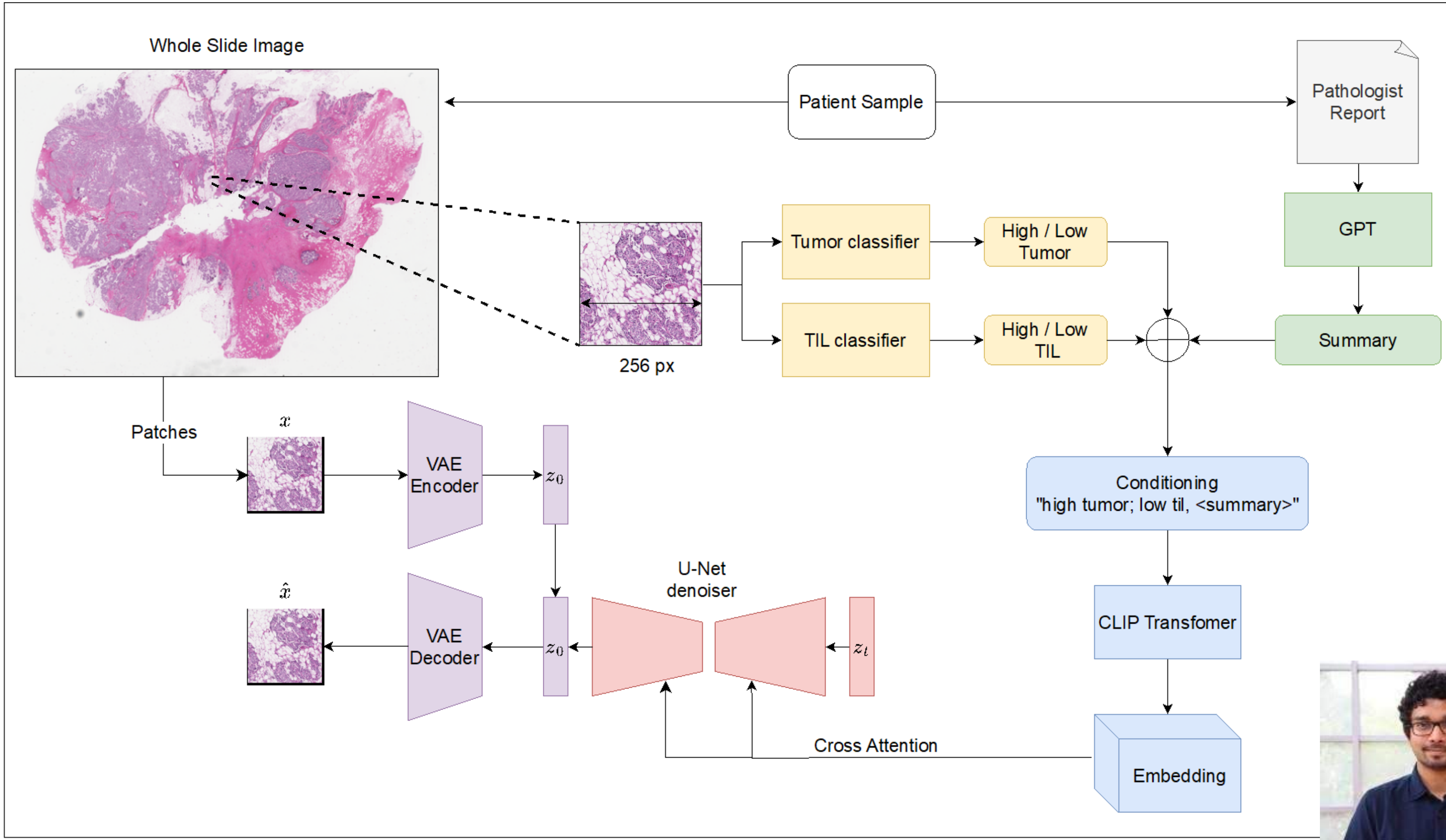

Yellapragada et al, WACV 2024

User

Extract information from breast pathology report. List the histological classification, i.e. type of cancer or DCIS, subtype, description of any necrosis, any mention of tumor infiltrating lymphocytes, histological grade, nuclear grade, lymphovascular invasion, calcification, receptor status, IHC and any other ancillary testing results. List out and expand the main points.

The report is

Subtype LumA, Path No.: Date Obtained: (Age: Date Received: F. See Addendum/Procedure. SPECIMEN: A:Lymph node, left axilla sentinel, biopsy. B:Breast, left, modified radical mastectomy. DIAGNOSIS(ES): A. Lymph node, left axilla sentinel, biopsy: --- Metastatic carcinoma, following carcinoma of breast. B. Breast, left, modified radical mastectomy:..

GPT

The breast pathology report indicates the following information:

1. Histological classification: The patient has Luminal A subtype breast cancer. The biopsy of the left axilla sentinel lymph node shows metastatic carcinoma following breast carcinoma.

2. Subtype: The invasive carcinoma is of the lobular type, poorly differentiated and multifocal, with extensive lymphatic permeation. Lobular neoplasia, type B (pleomorphic), is widespread. The report also mentions fibrocystic disease, proliferative, with atypia.

3. Necrosis: No mention of necrosis.

4. Tumor infiltrating lymphocytes: The report mentions extensive lymphatic permeation but does not mention tumor infiltrating lymphocytes.

User

Please generate a succinct report in 75 words from the above information. Exclude any filler words or sentences. If something is not mentioned or specified, exclude it from the report. Low verbosity.

GPT

Report: Luminal A subtype breast cancer with metastatic carcinoma in axillary lymph nodes. Invasive carcinoma is of lobular type, poorly differentiated and multifocal, with extensive lymphatic permeation. Pleomorphic lobular neoplasia type B and cystic disease found. Nuclear grade 3, positive estrogen receptor and progesterone receptor expression with no Her-2/neu overexpression. Lymphovascular invasion present in lymphatics. No necrosis or tumor infiltrating lymphocytes mentioned.

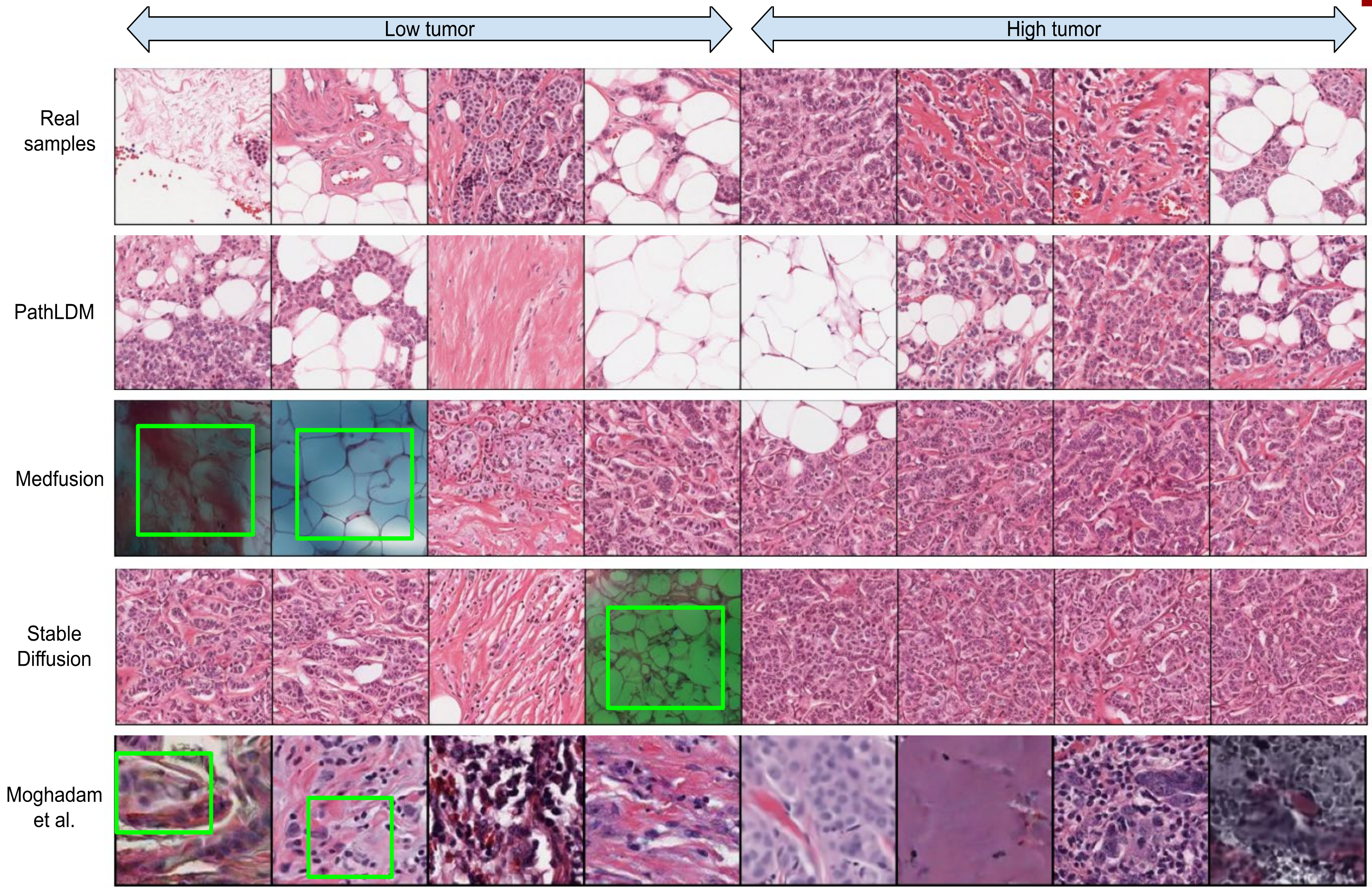
Low tumor
High tumor
Real samples
PathLDM
Medfusion
Stable Diffusion
Moghadam et al.

Attention Diversity Matters!

Kapse et al. MedIA, 2024

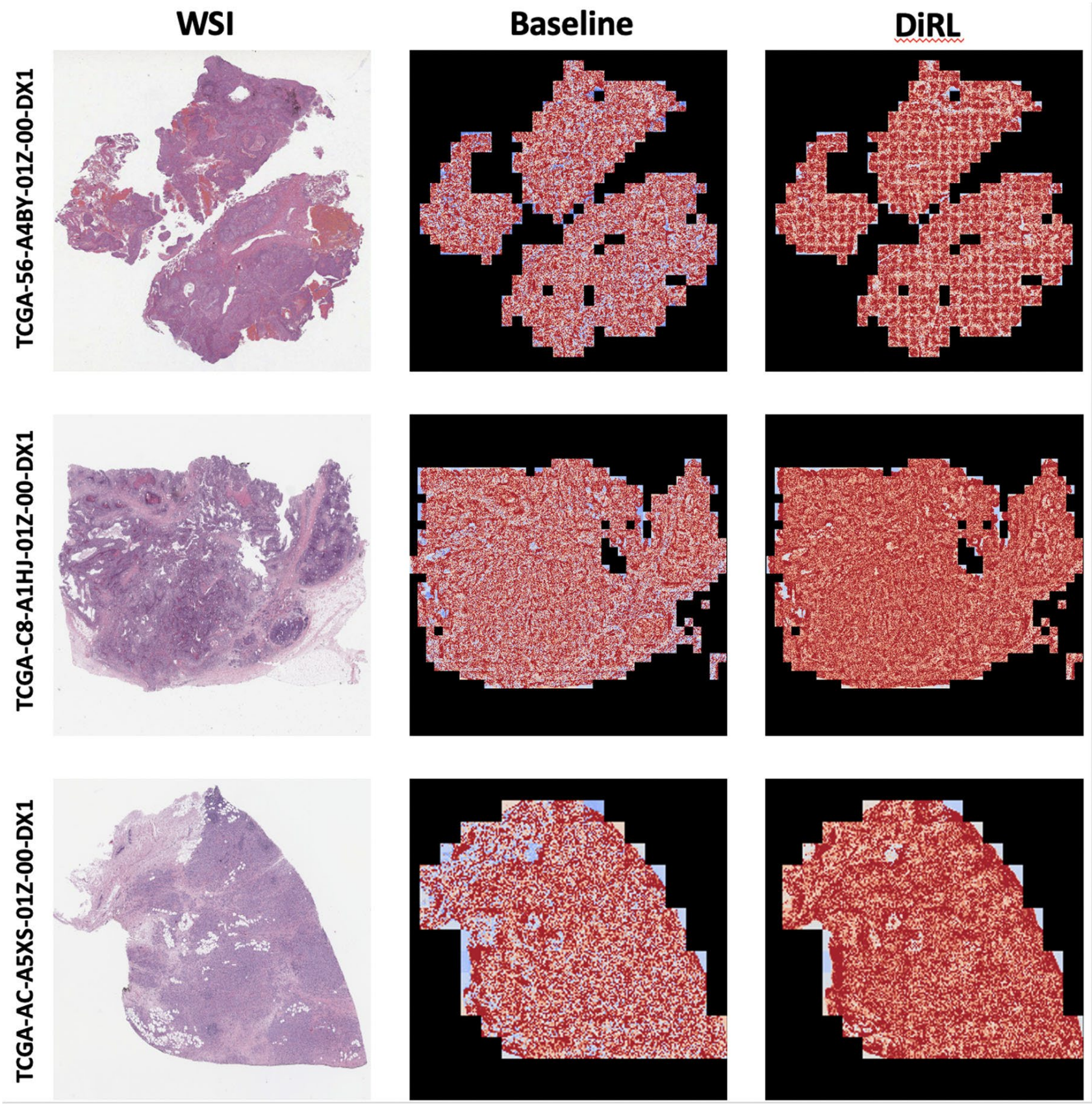
WSI
Baseline
DiRL
TCGA-56-A4BY-01Z-00-DX1
TCGA-C8-A1HJ-01Z-00-DX1
TCGA-AC-A5XS-01Z-00-DX1

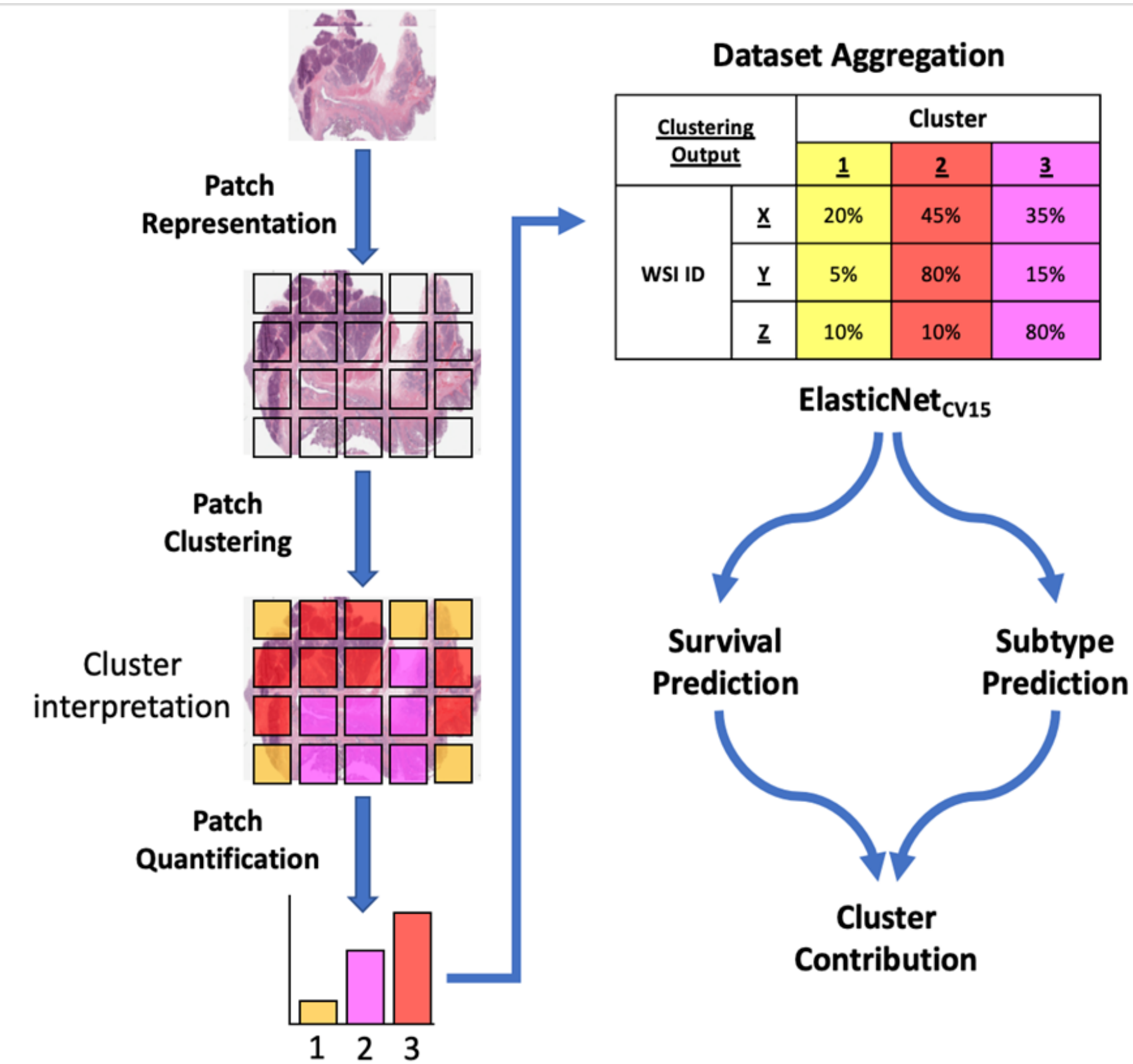
Patch Representation
Patch Clustering
Cluster interpretation
Patch Quantification
1 2 3
Dataset Aggregation
Clustering Output
Cluster
1
2
3
WSI ID
X 20% 45% 35%
Y 5% 80% 15%
Z 10% 10% 80%
ElasticNet CV15
Survival Prediction
Subtype Prediction
Cluster Contribution

Pancreatic cancer - Basal

Cluster	HR Beta	Subtype Beta	Description (Raj)	Parsed Description
2	0.14	0.71	Stroma+Tumor	TME, Stroma+Tumor
13	0.11	0.29	Normal+Tumor	TME, Stroma+Tumor
4	0.07	0.25	Small dark nuclei	Small round black nuc

2

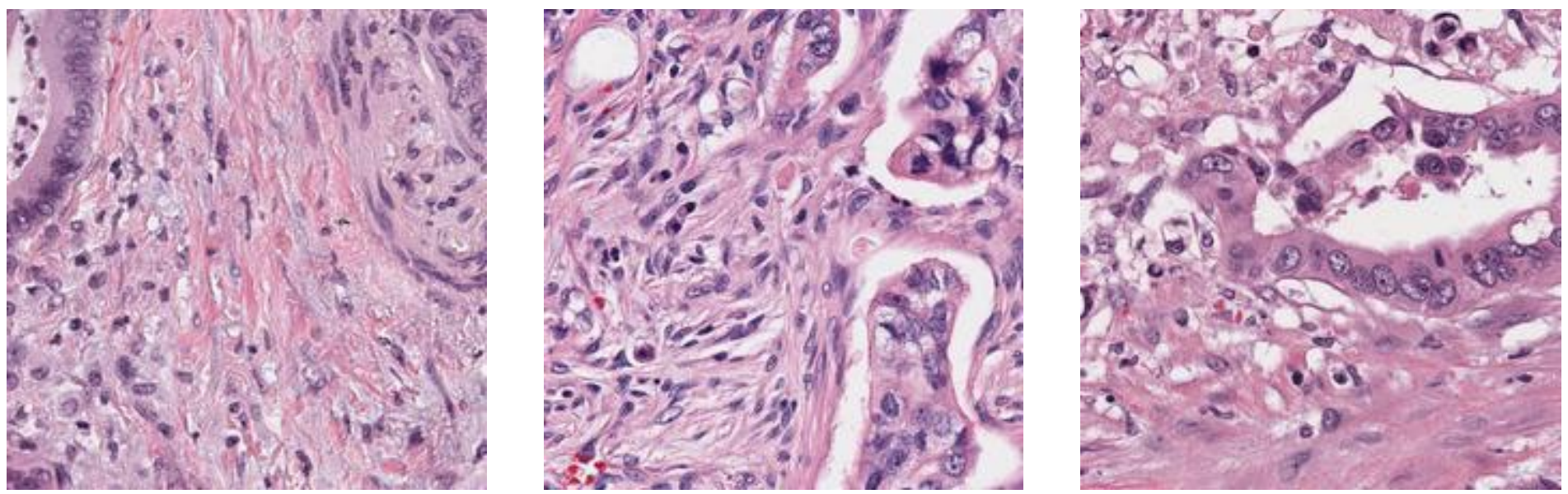

13

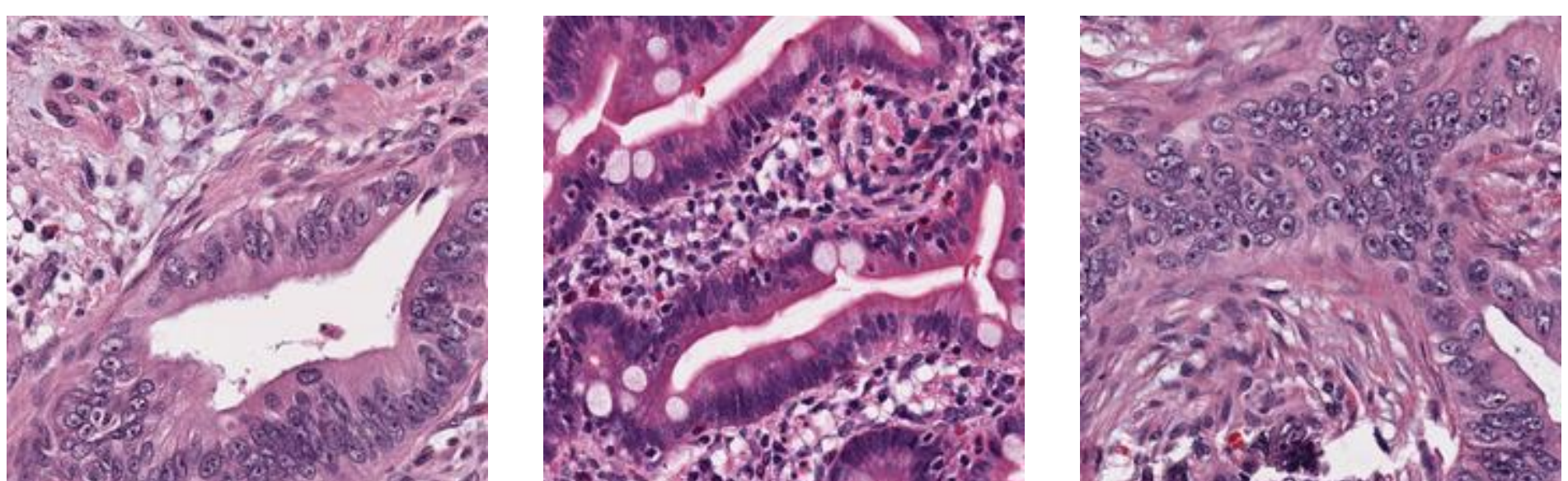

4

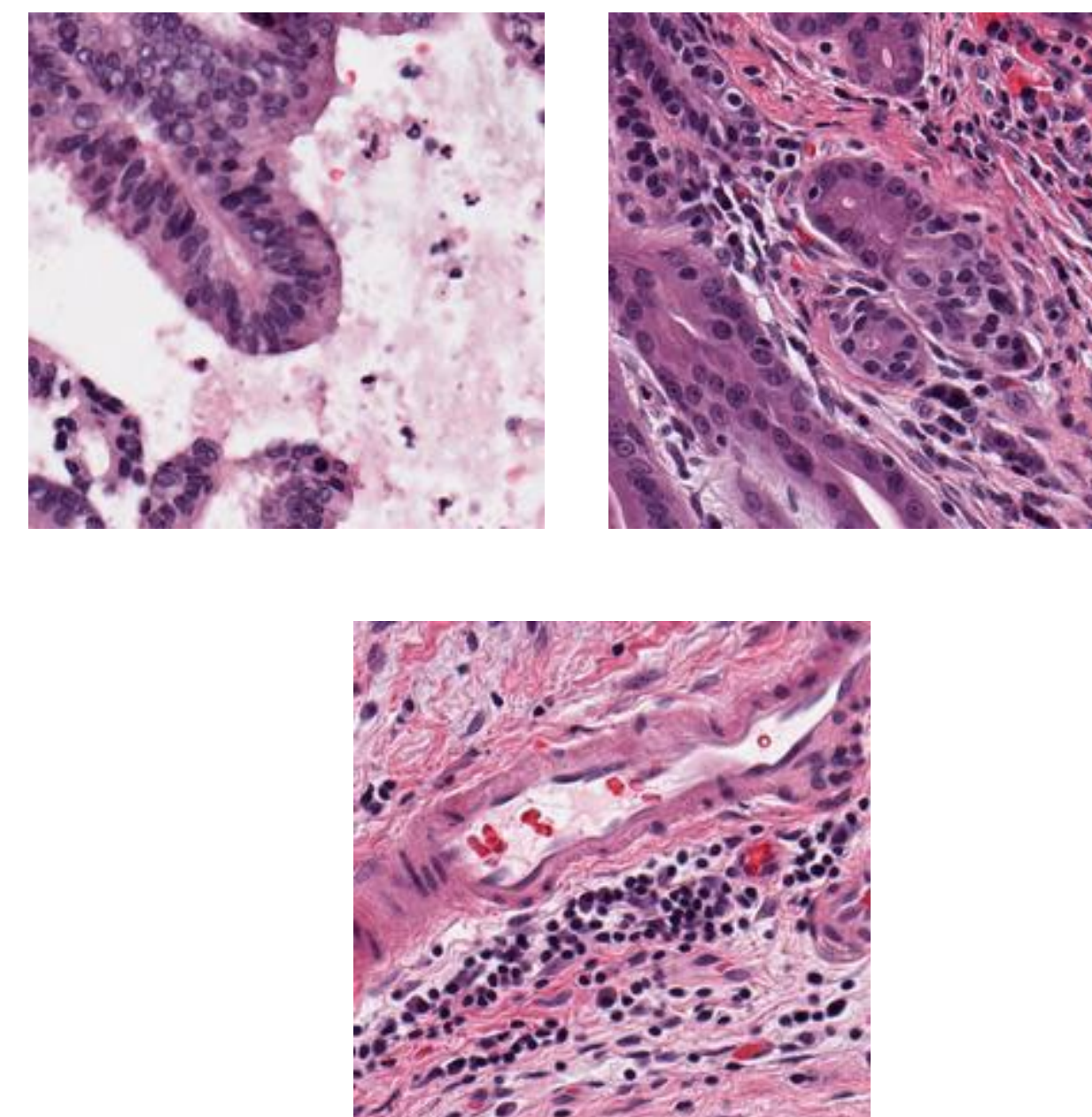

Pancreatic cancer - Classical

9	0.06	-0.92	Desmoplastic stroma +/- tumor, n	TME, Stroma+Tumor
7	-0.03	-1.4	Bright pink	Bright pink, wavey
20	0.27	-2.93	Lymph	Lymph Invasion

20

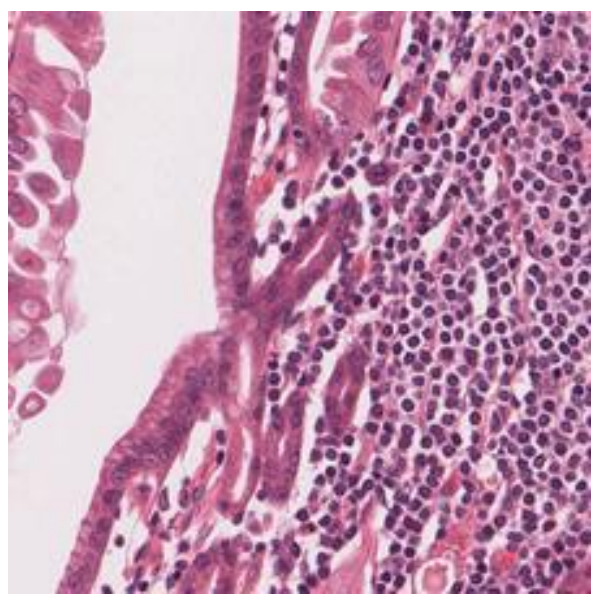

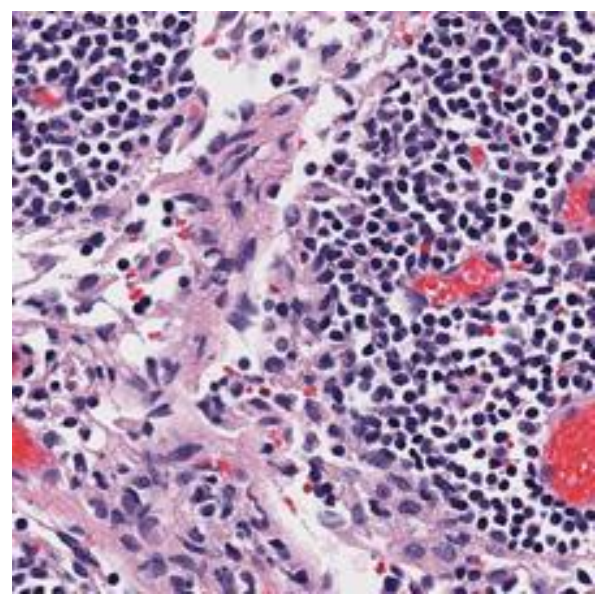

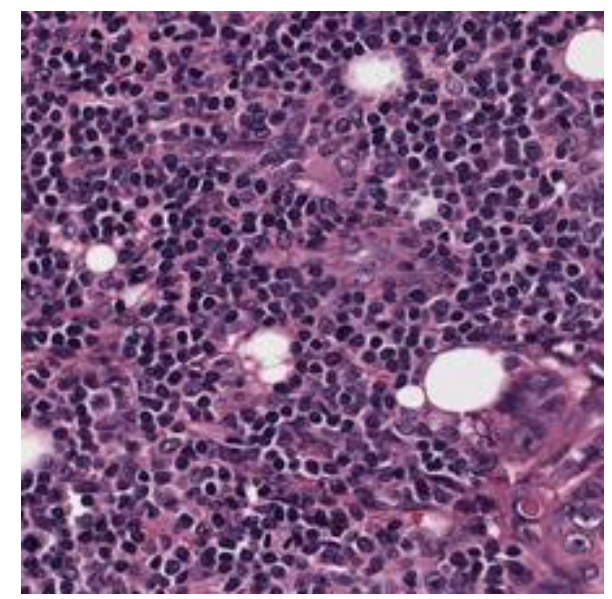

7

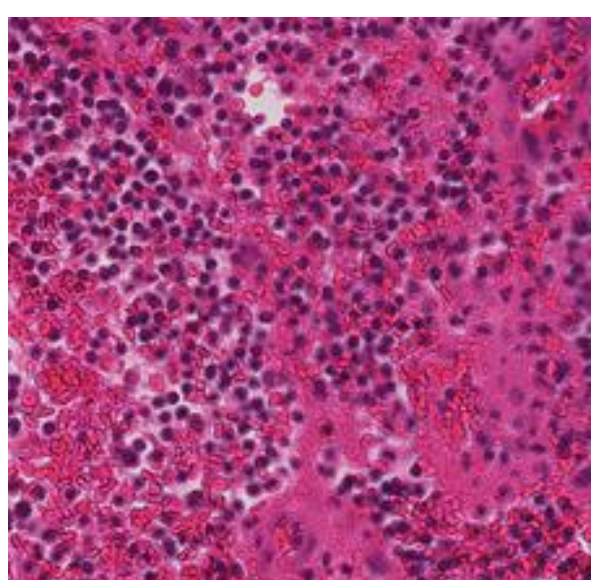

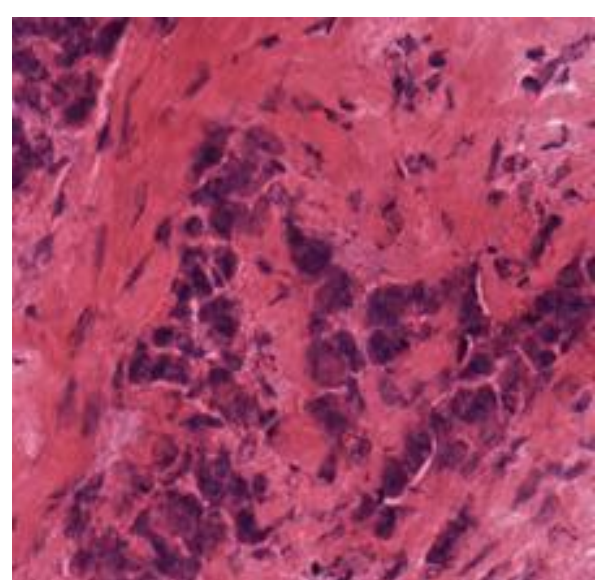

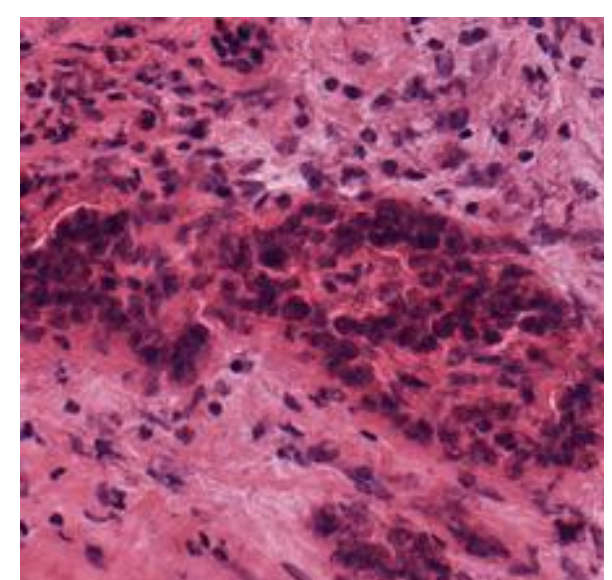

18

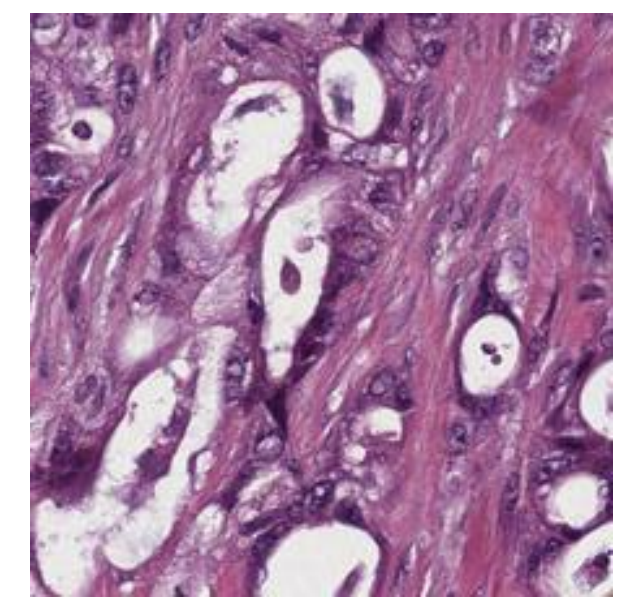

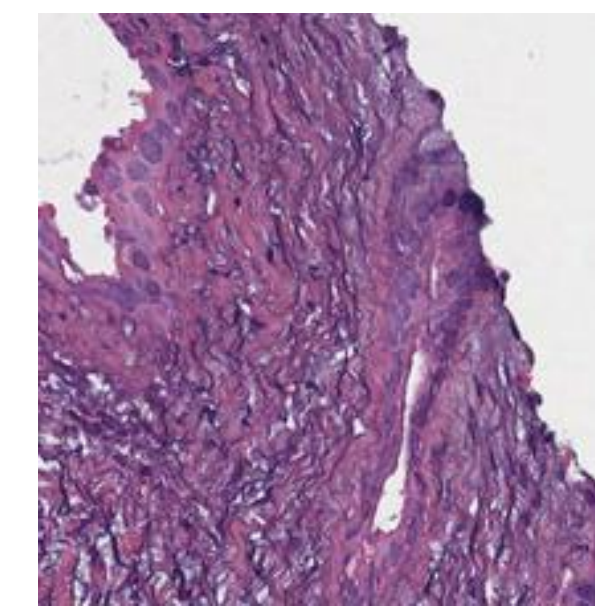

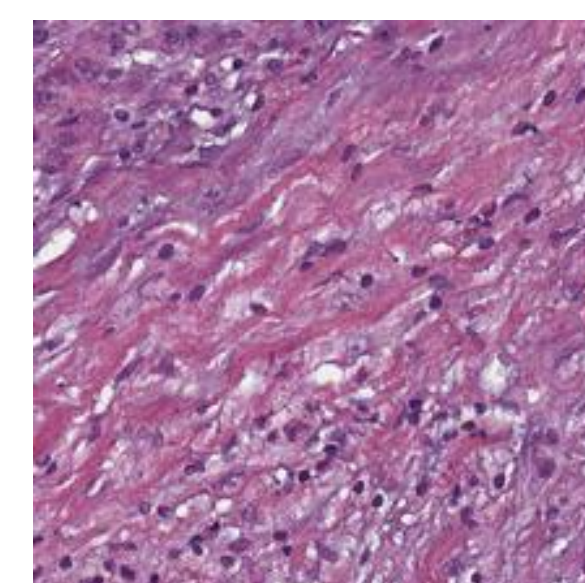

ACKNOWLEDGEMENTS

NIH National Institutes of Health

Rutgers Robert Wood Johnson Medical School

Cleveland Clinic

Weill Cornell Medicine



Henry Ford Health System

Columbia University in the City of New York

Thank you

Prateek.Prasanna@stonybrook.edu